

Beeldvorming & Interventies in congenitale hartafwijkingen in het WKZ / UMCU

Mirella Molenschot

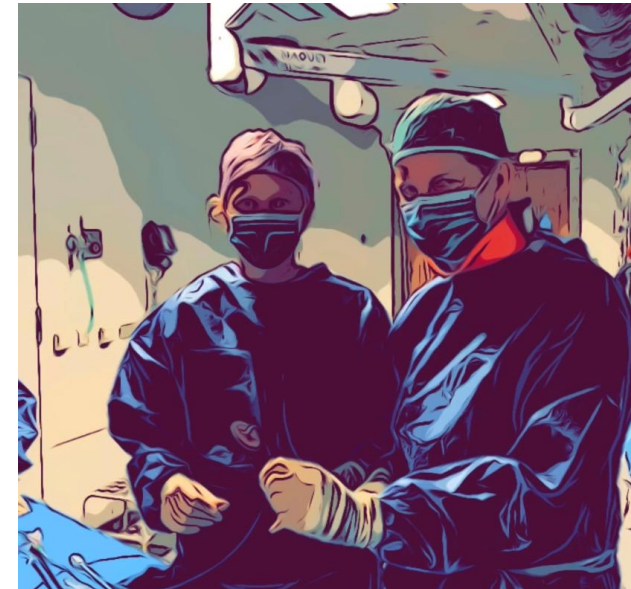Interventie-kindercardioloog



UMC Utrecht

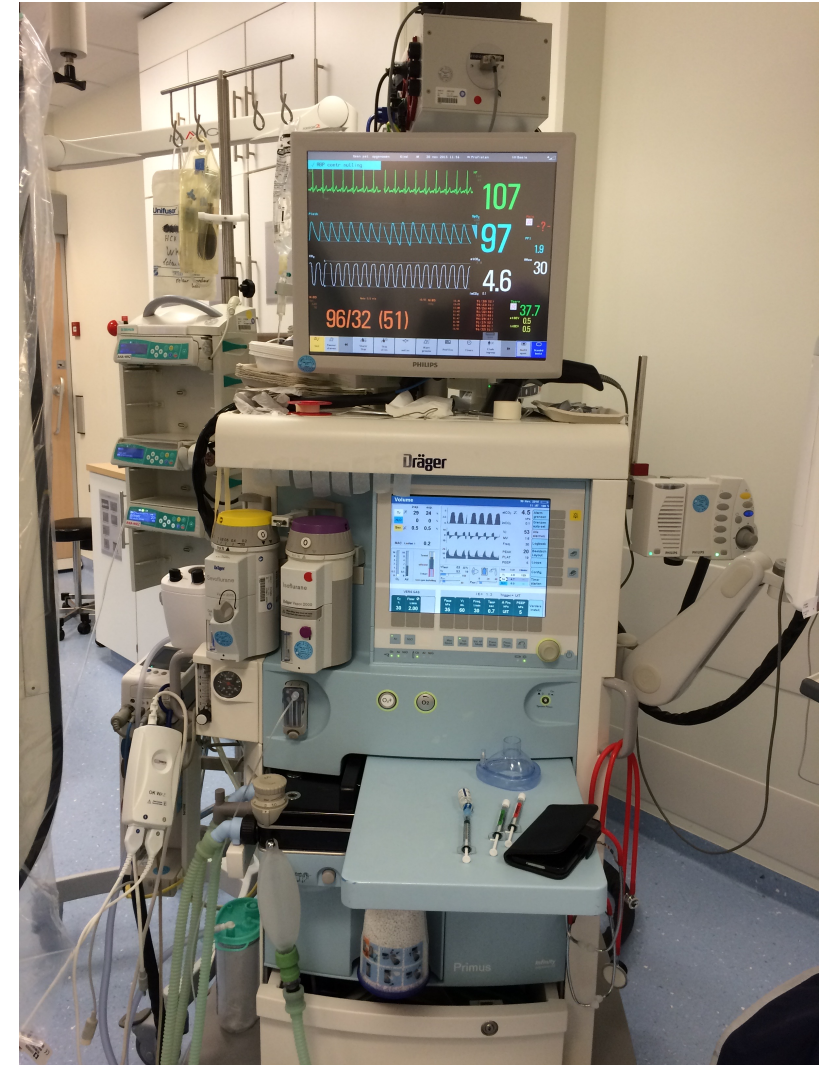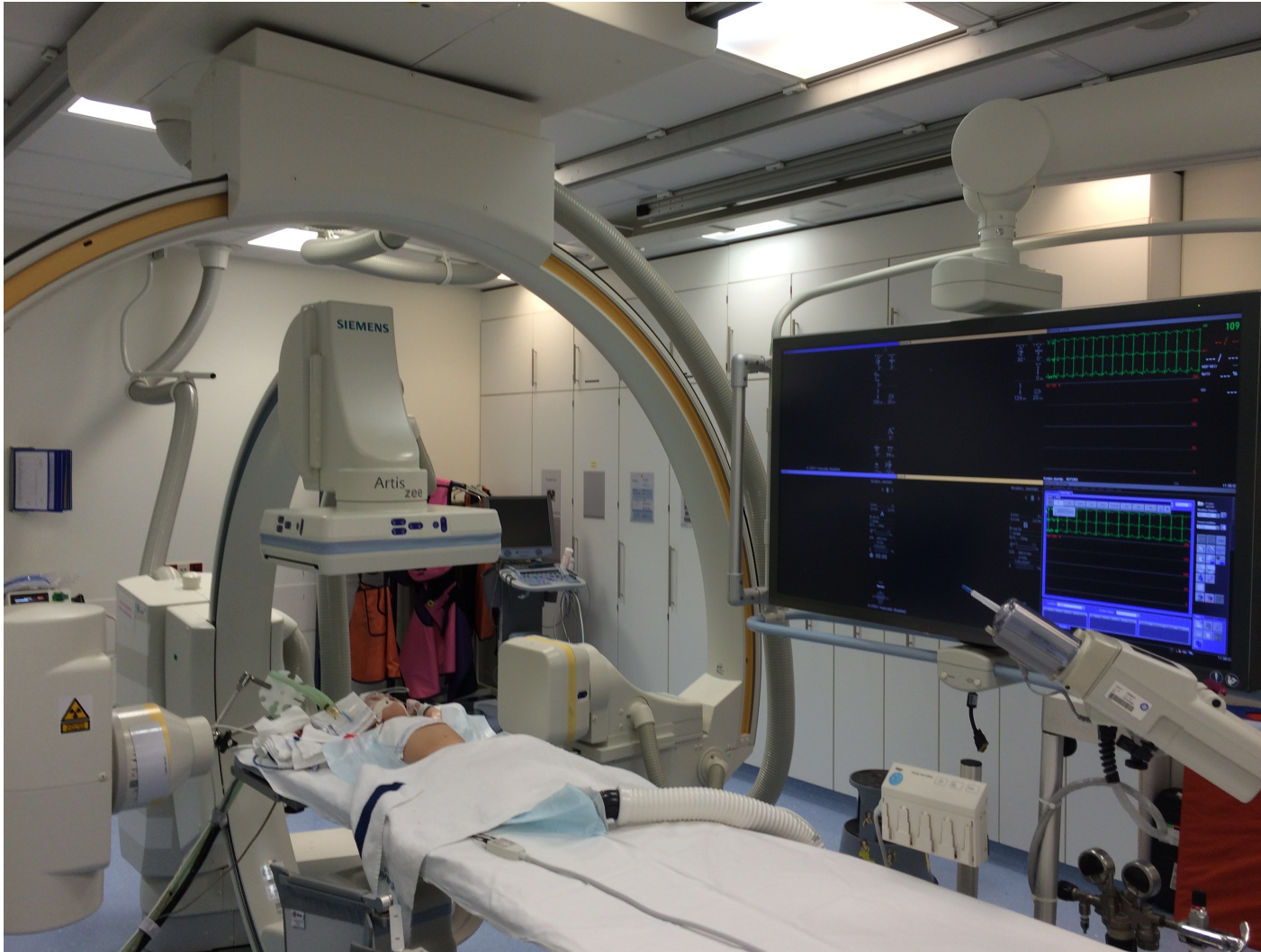Wilhelmina Kinderziekenhuis

Ons (kinder) hartcatheterisatie team

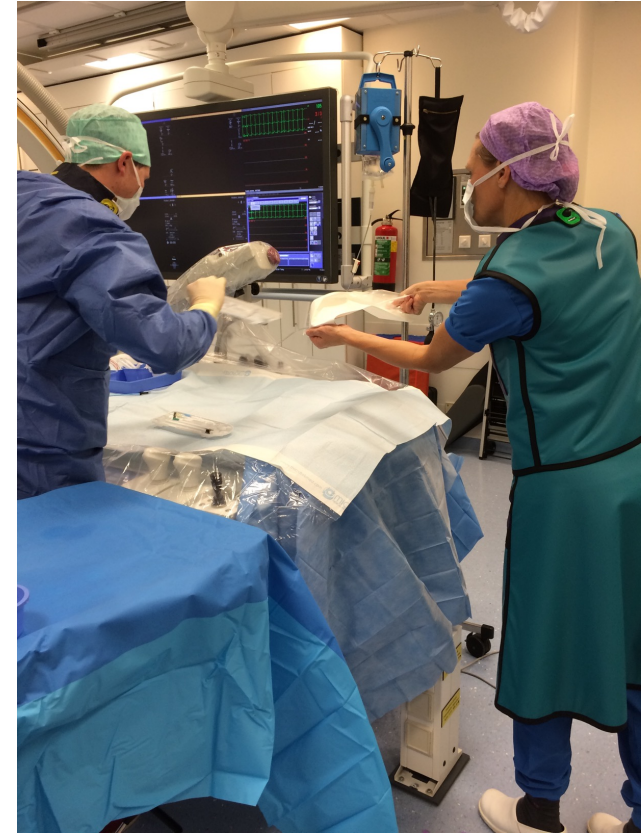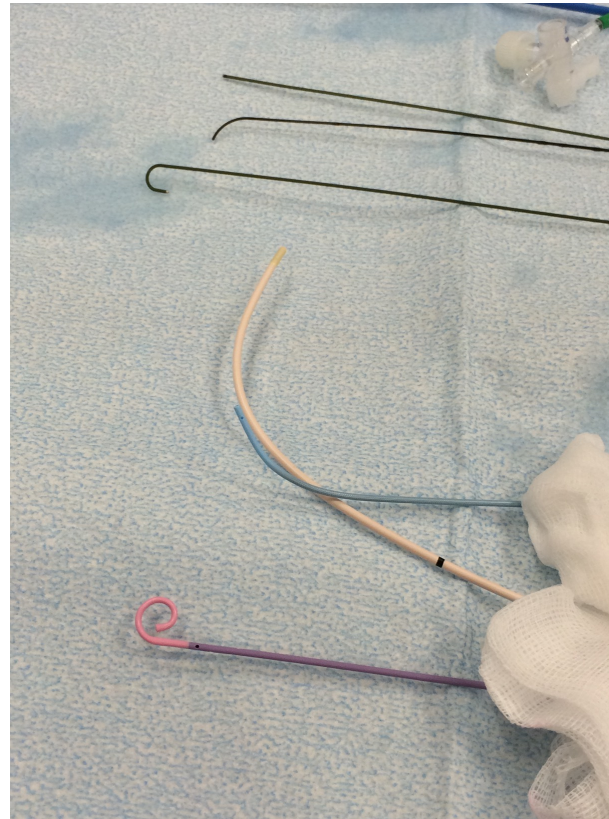
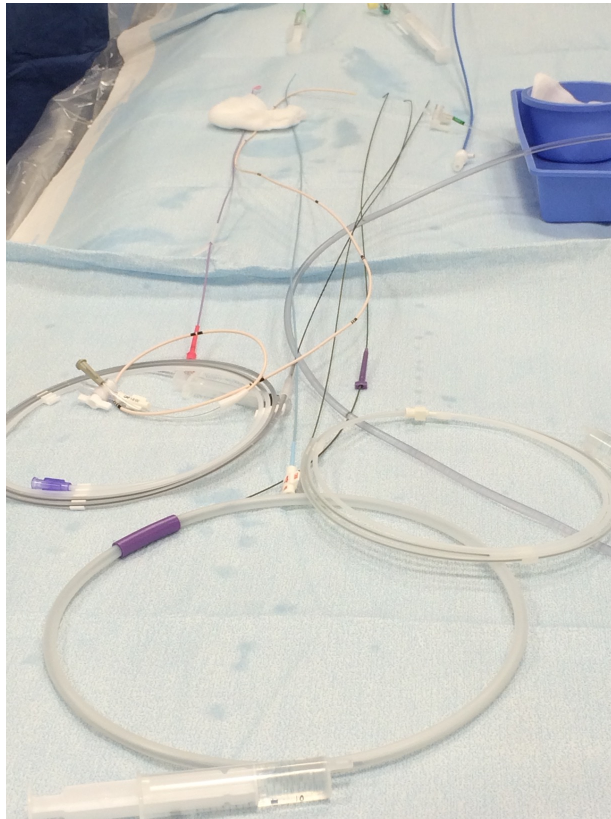
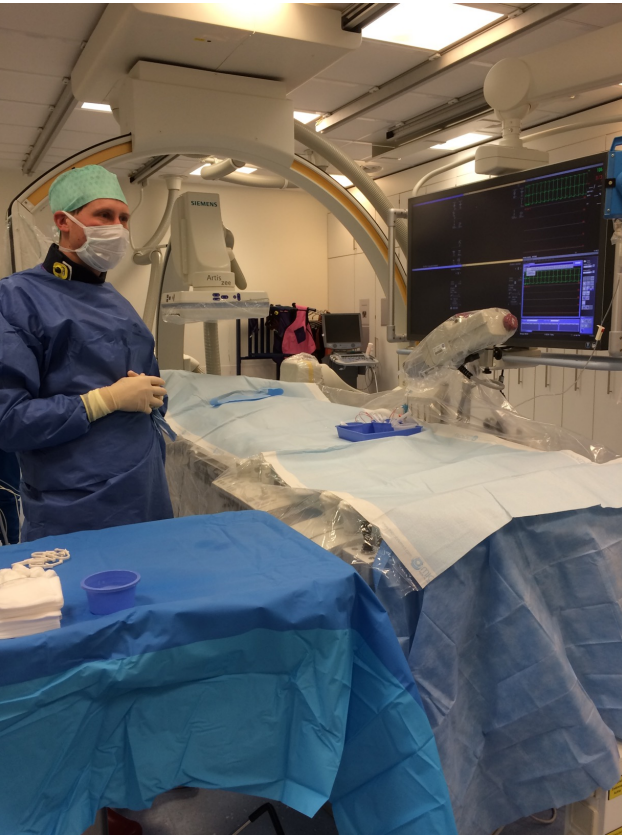


Wat is een hartcatheterisatie ?

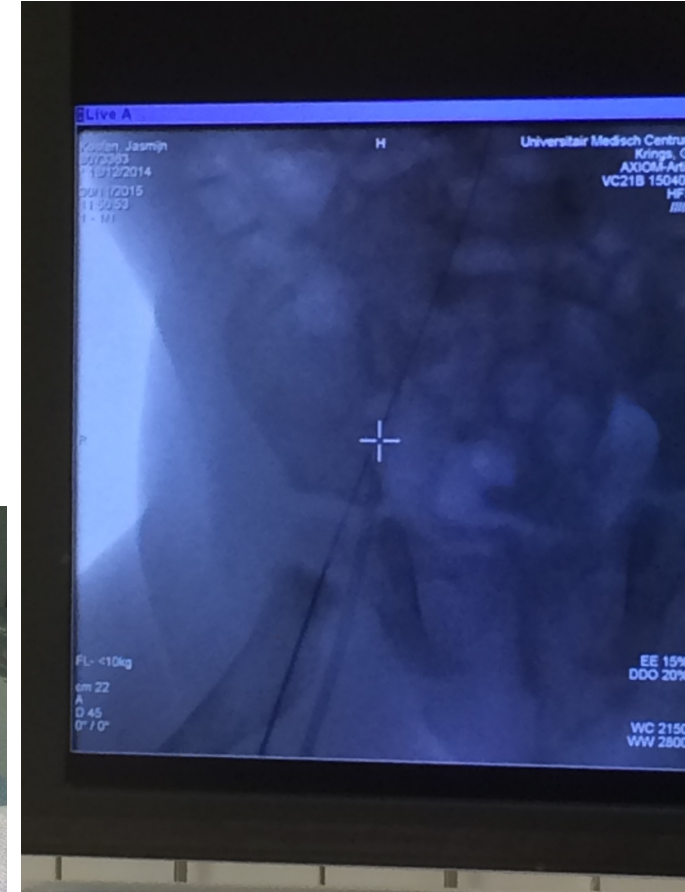
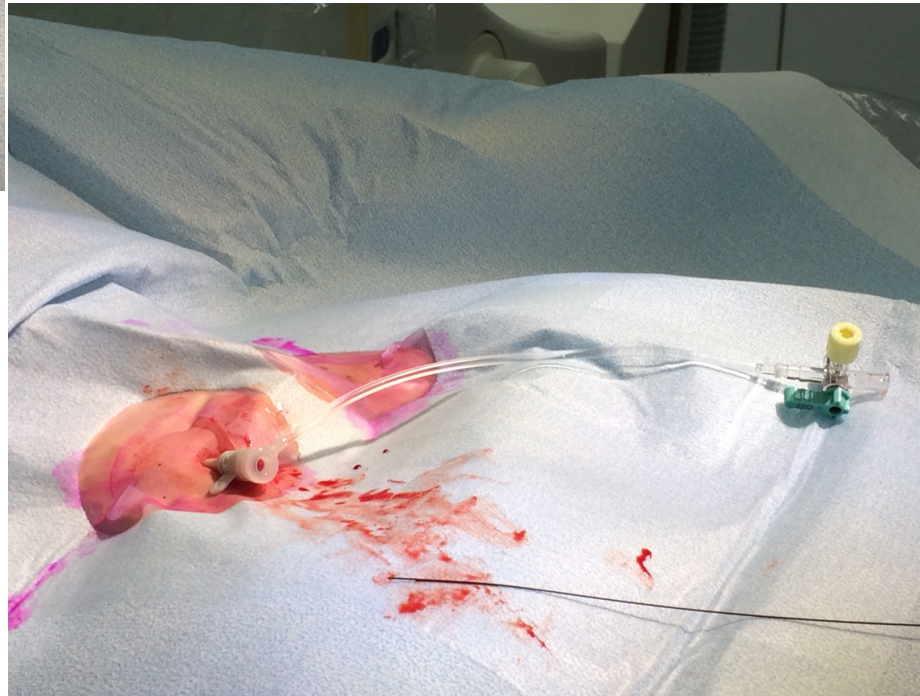
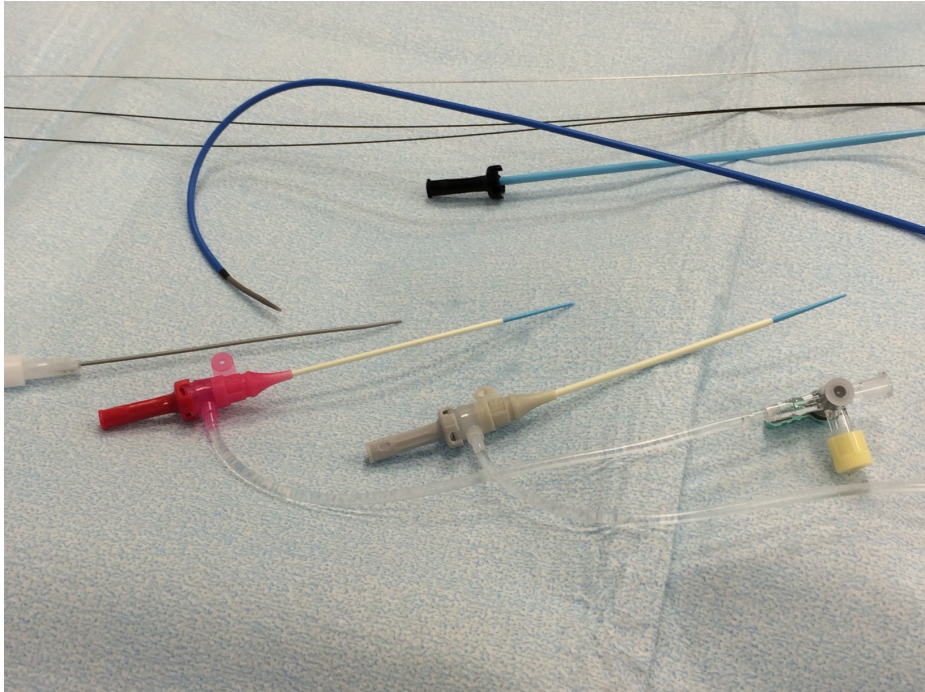
Wat is een hartcatheterisatie ?



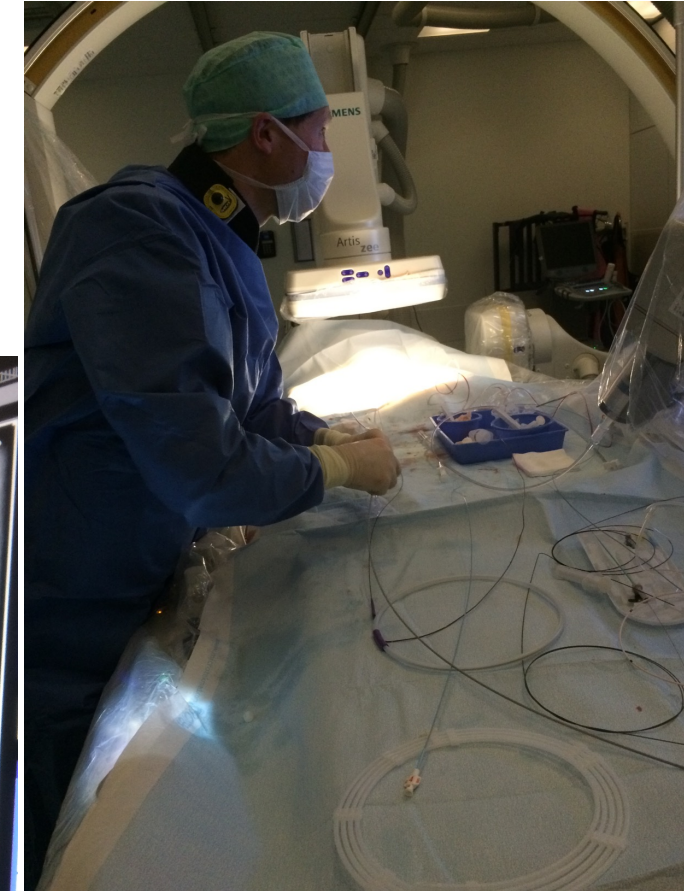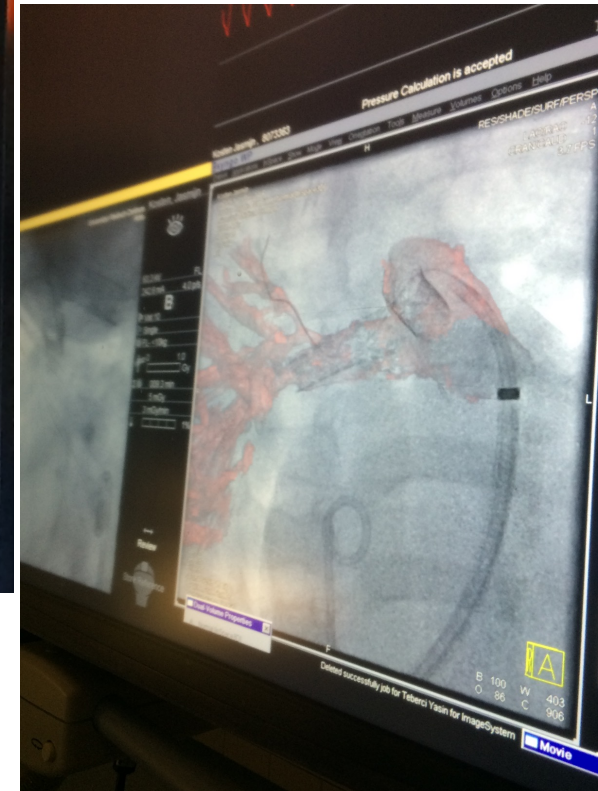
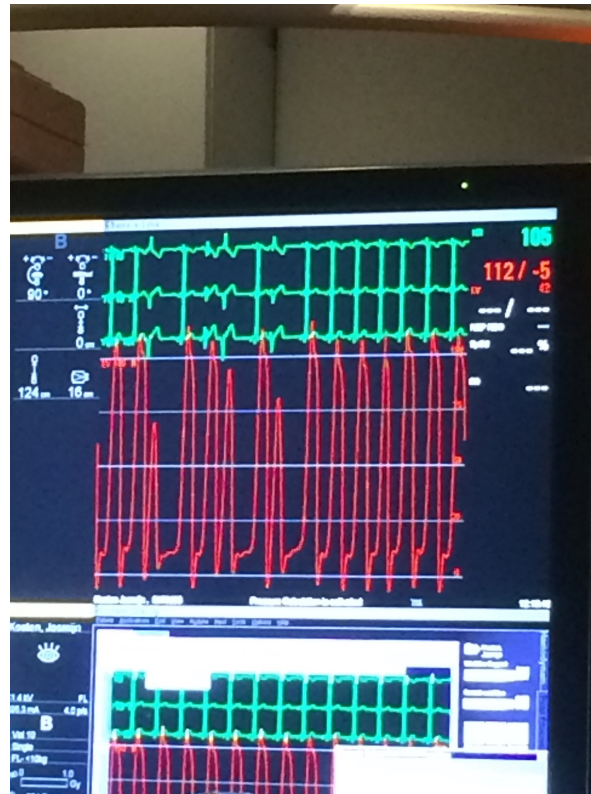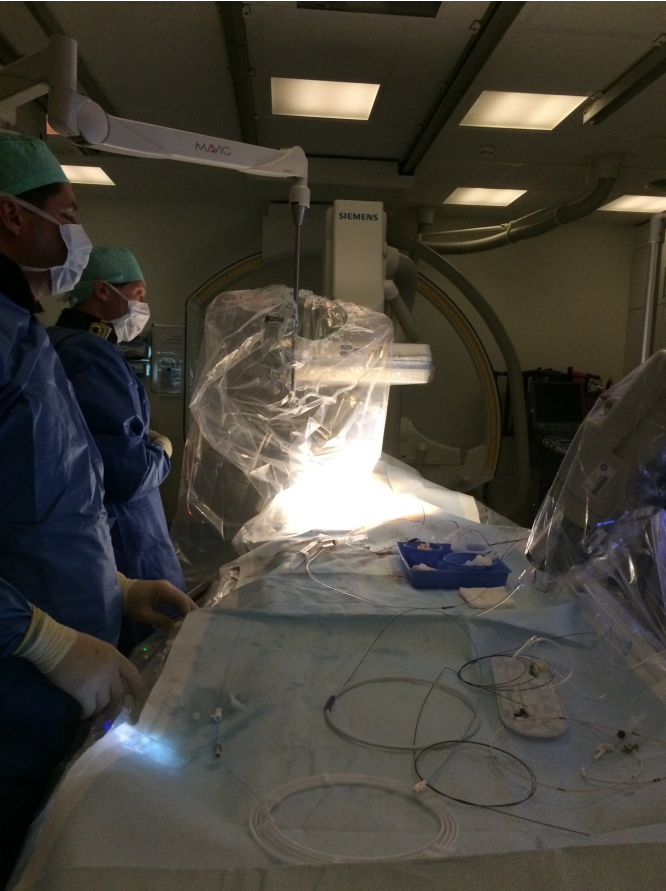
Wat is een hartcatheterisatie ?



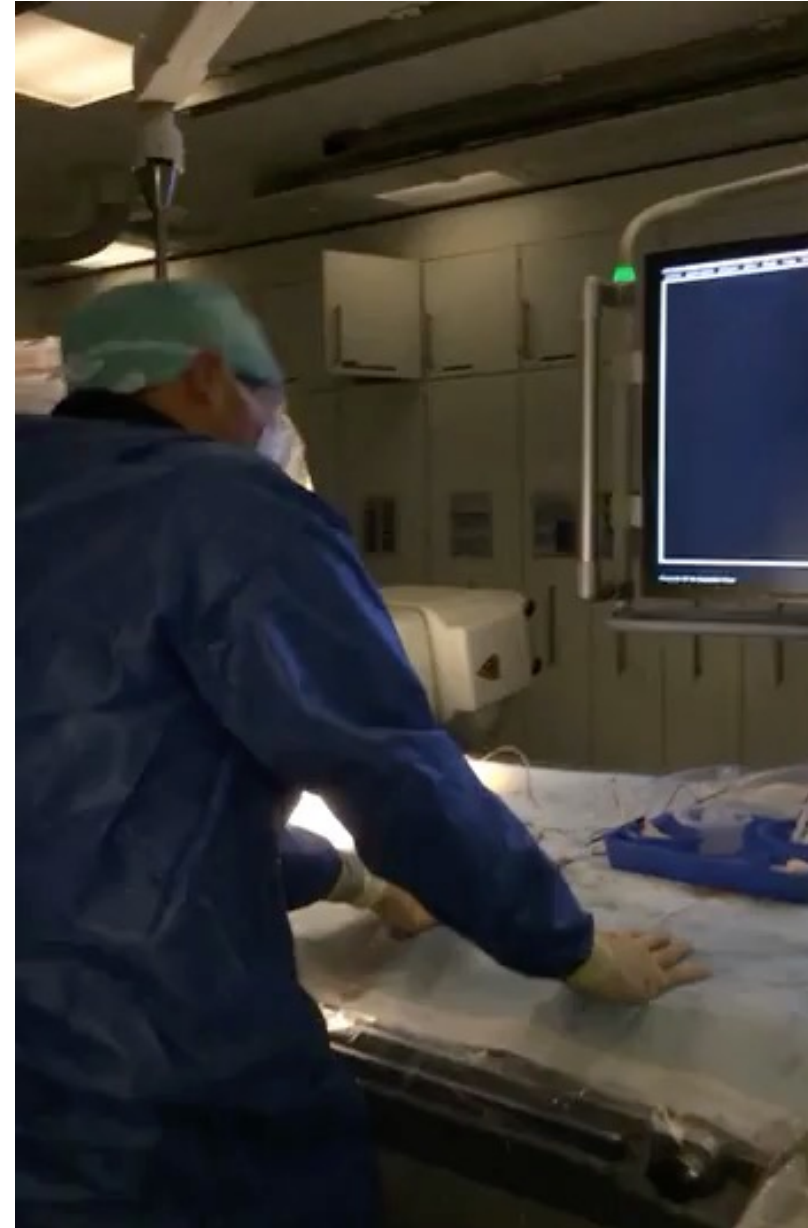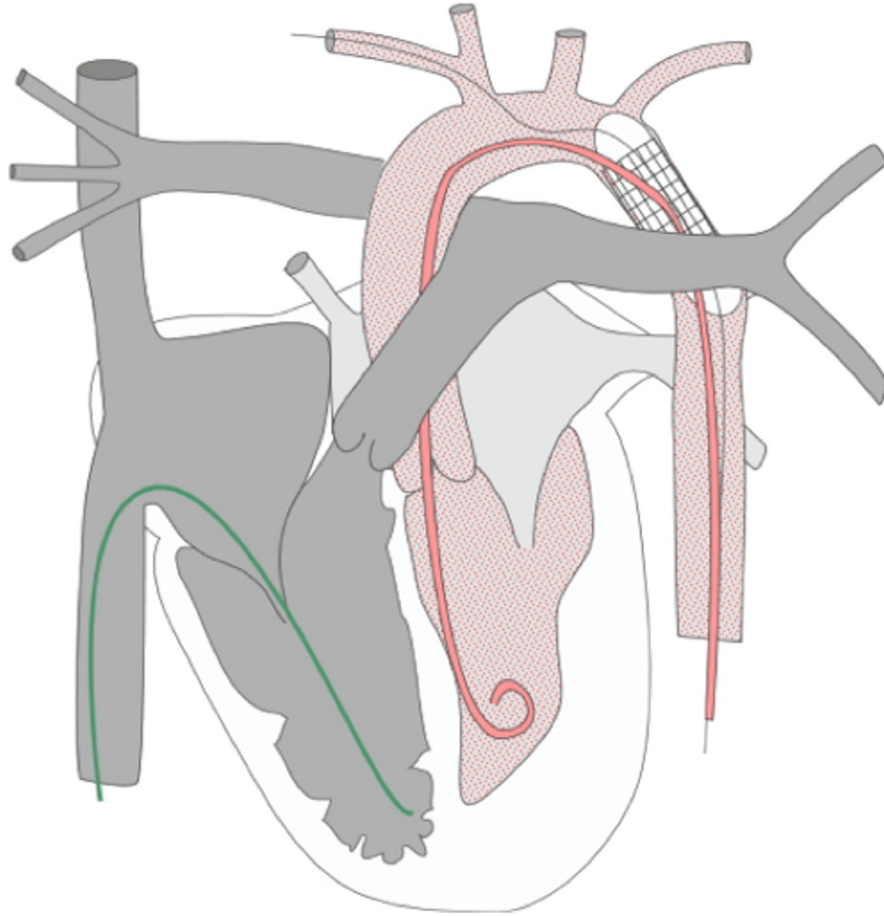
Wat is een hartcatheterisatie ?



Wat is een hartcatheterisatie ?



Speerpunt Utrecht: 3D beeldvorming tijdens hartcatheterisatie



Wanneer of waarom is een hartcatheterisatie nodig ?

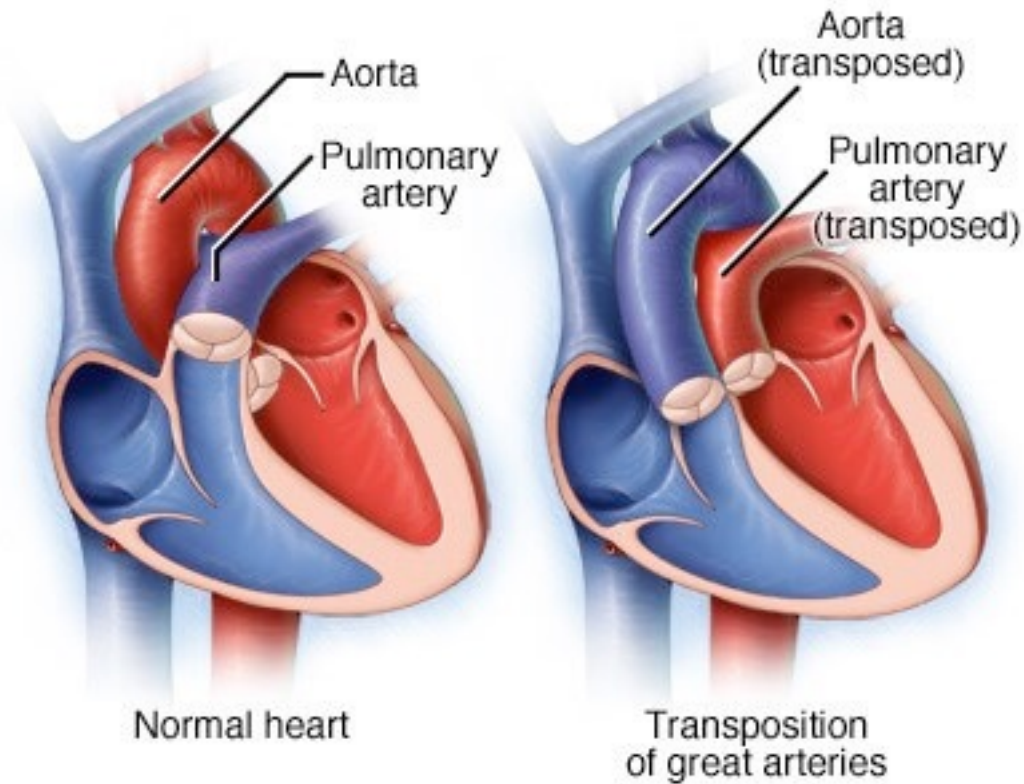
- Vlak na geboorte
 - Overbrugging tot aan operatie
 - Oplossing voor langere termijn (vervangt dan een open hart operatie)
 - Nadere beeldvorming ('diagnostisch')
- Na een eerdere (open) hart operatie
 - Nieuw probleem
 - Gevolg van oorspronkelijke hartafwijking
 - Gevolg van eerdere operatie
- Op kinder- / volwassen leeftijd
 - Als therapie i.p.v open hart operatie
 - diagnostisch

Voorbeeld catheterisatie vlak na geboorte

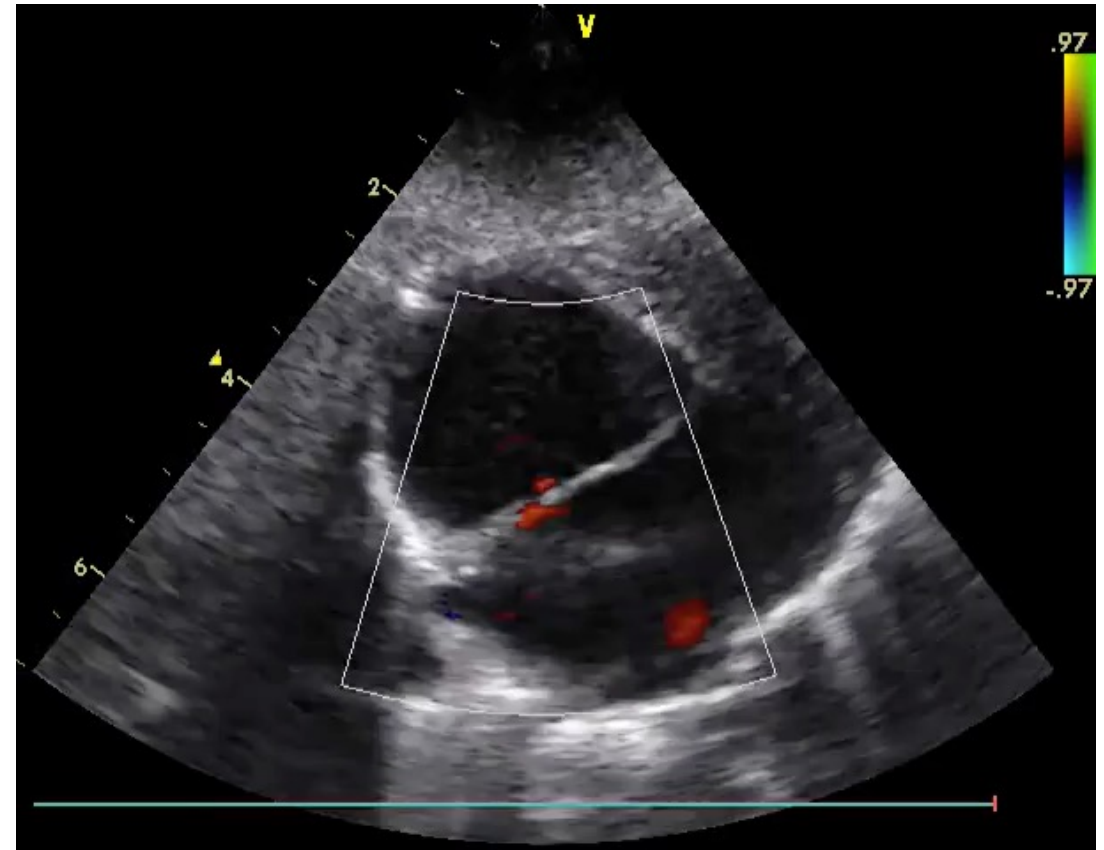
Overbrugging tot aan operatie

Rashkind procedure

Transpositie van de grote vaten

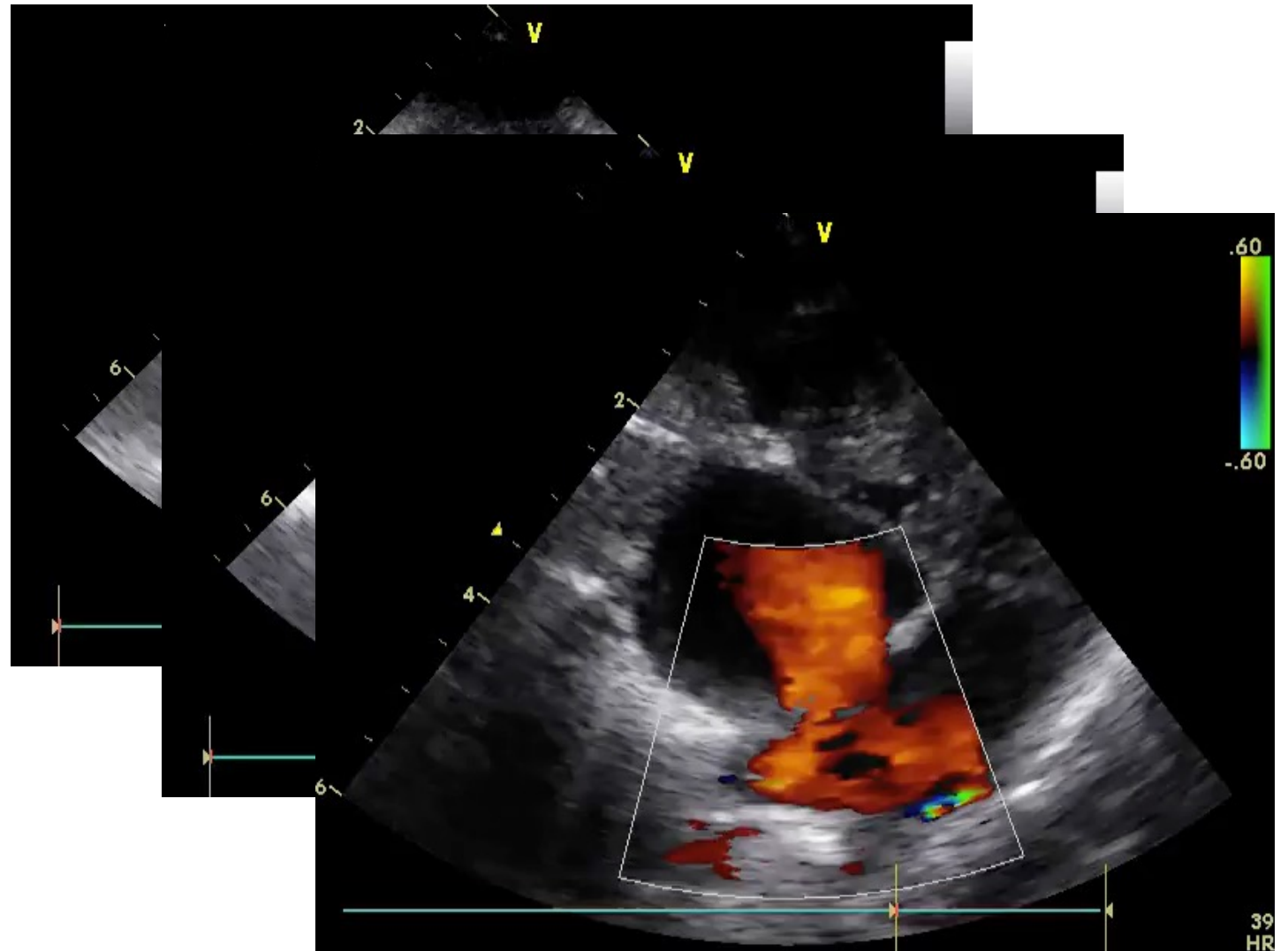
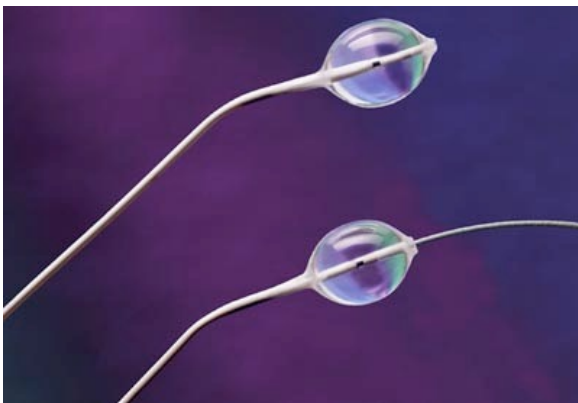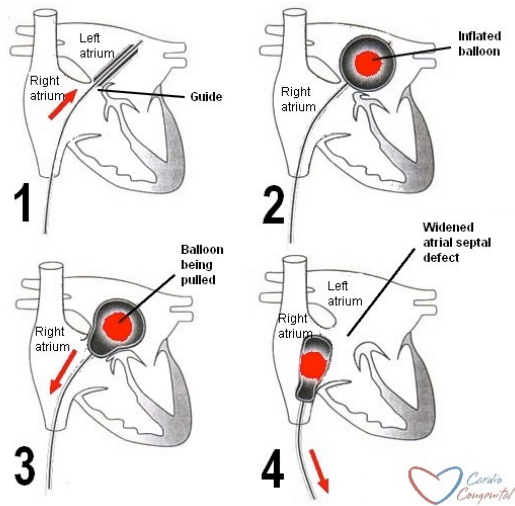


© MAYO FOUNDATION FOR MEDICAL EDUCATION AND RESEARCH. ALL RIGHTS RESERVED.



Rashkind procedure

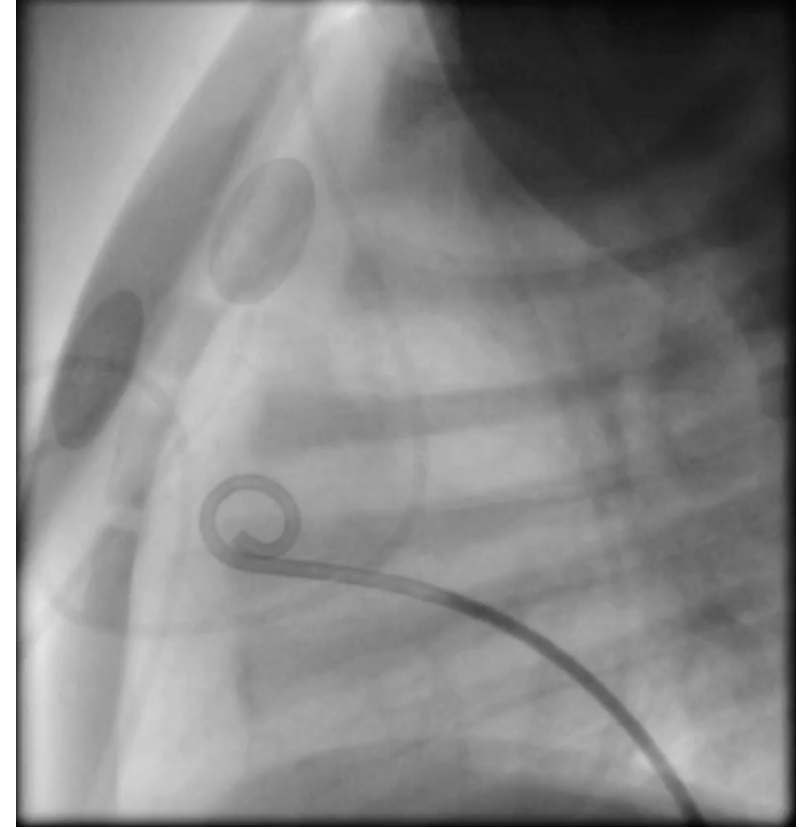
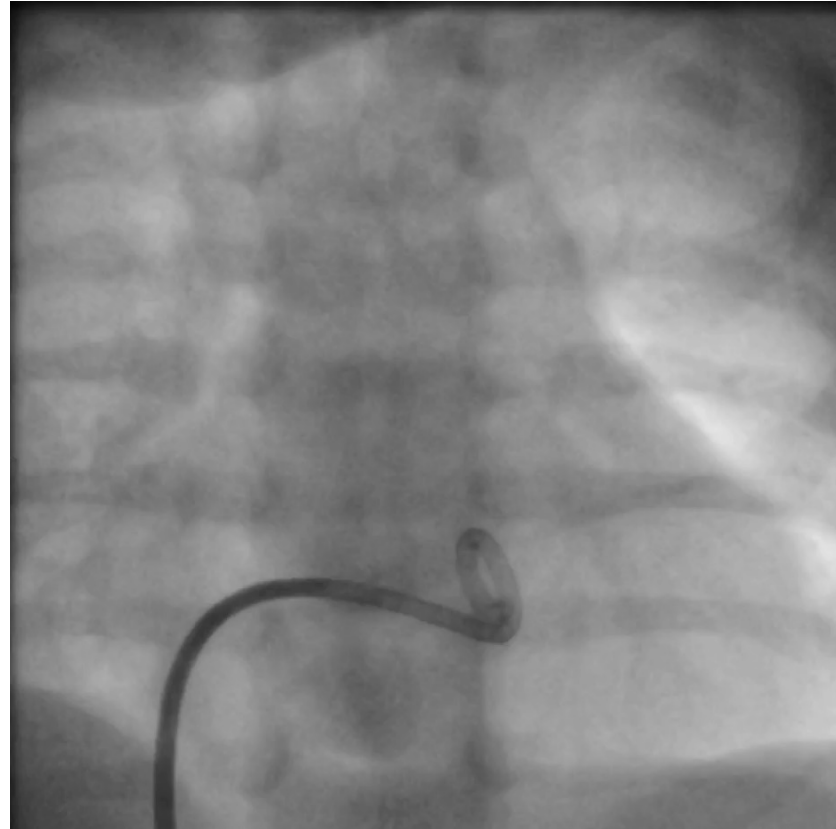
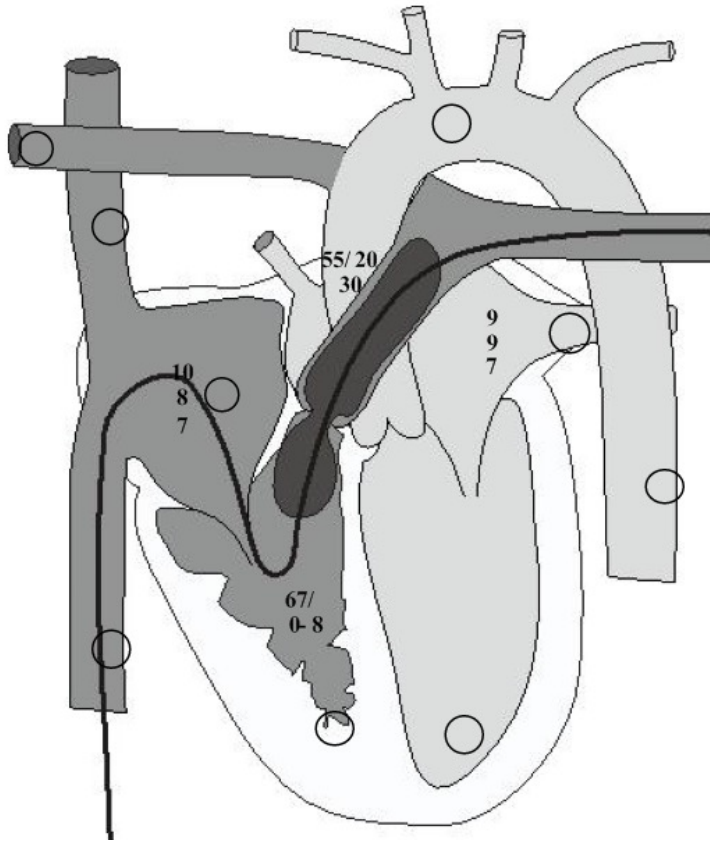
Rashkind balloon atrial septostomy



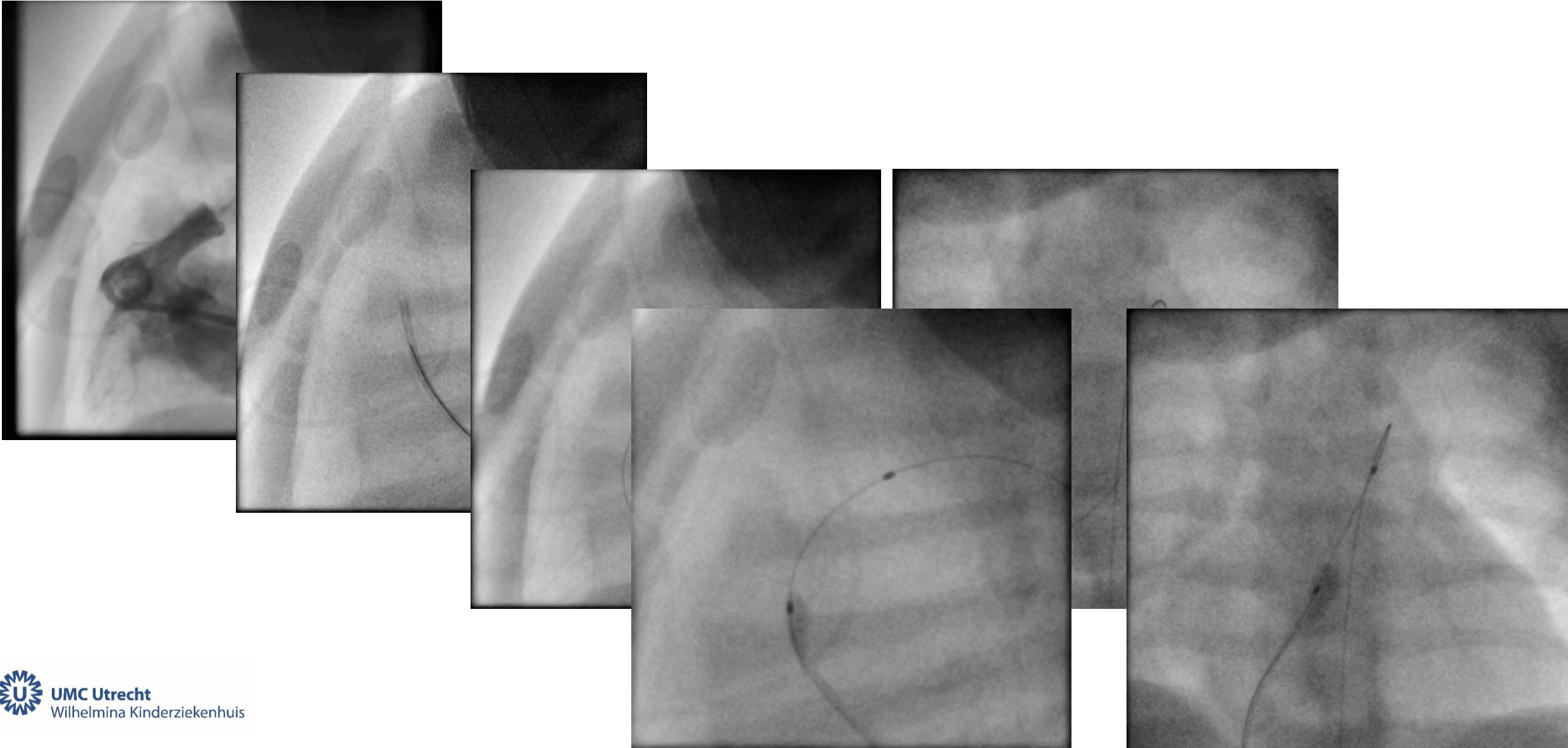
Voorbeeld catheterisatie vlak na geboorte of op zuigelingenleeftijd

In plaats van (open) hart operatie

Ballondilatatie longslagaderklep



Ballondilatatie longslagaderklep

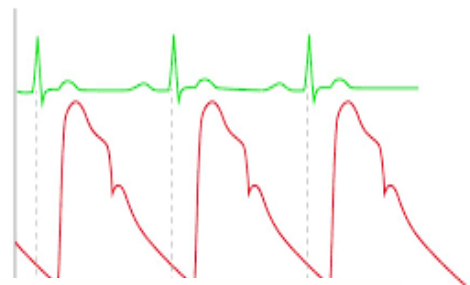
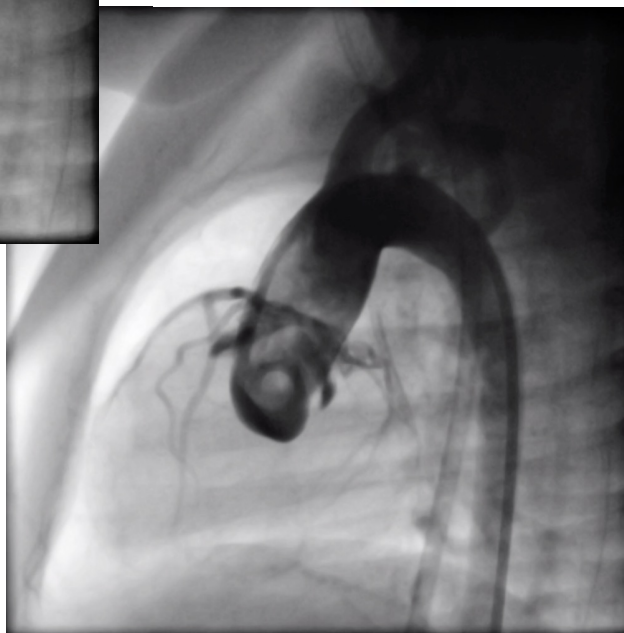
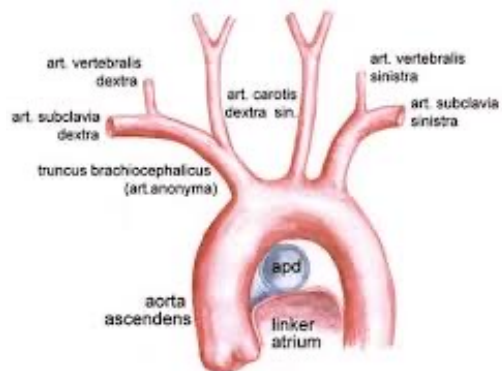
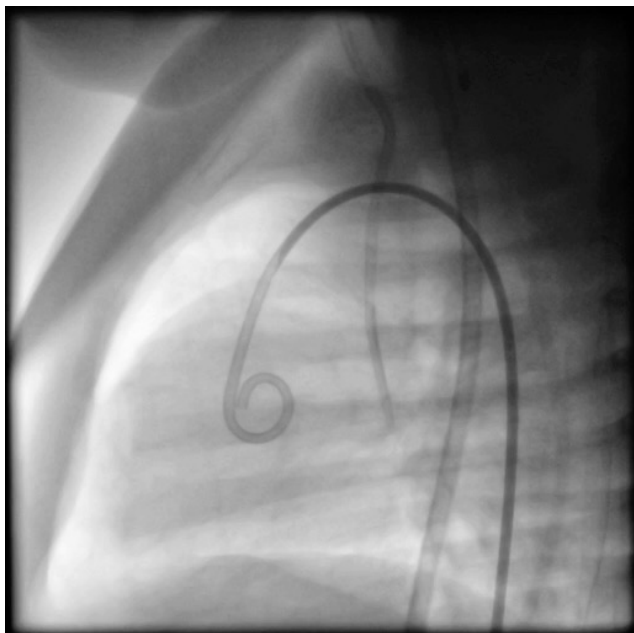


Voorbeeld catheterisatie na eerdere hartoperatie

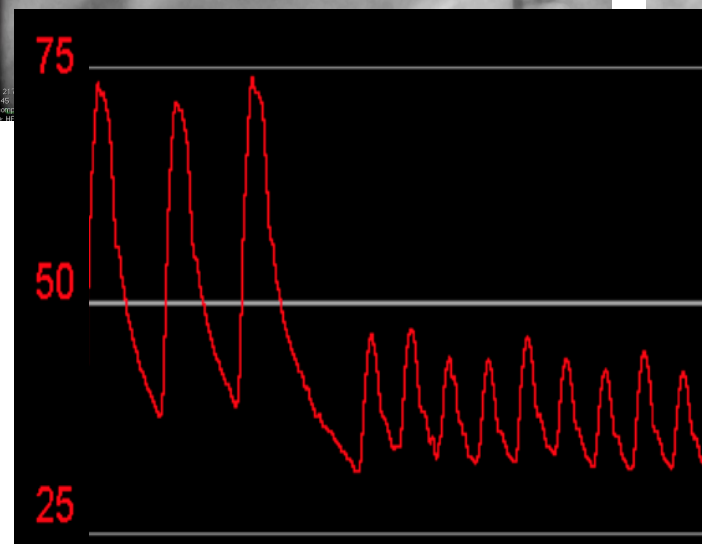
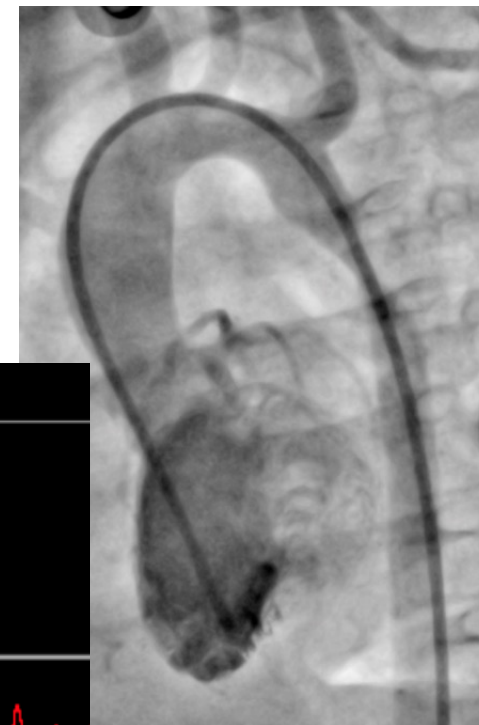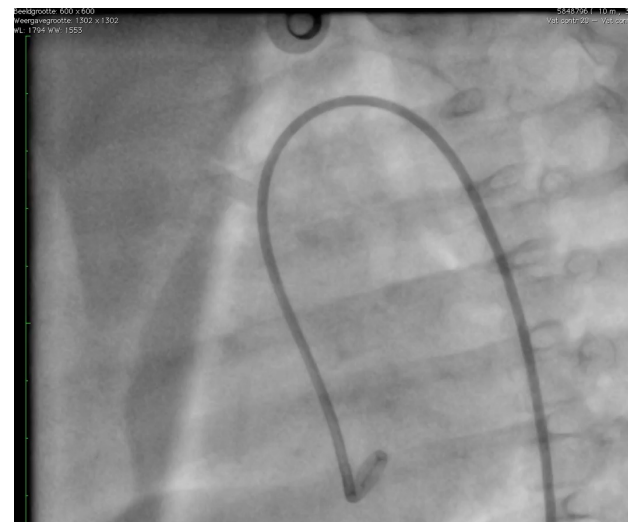
In plaats van re- operatie

Re- Coarctatie van de Aorta

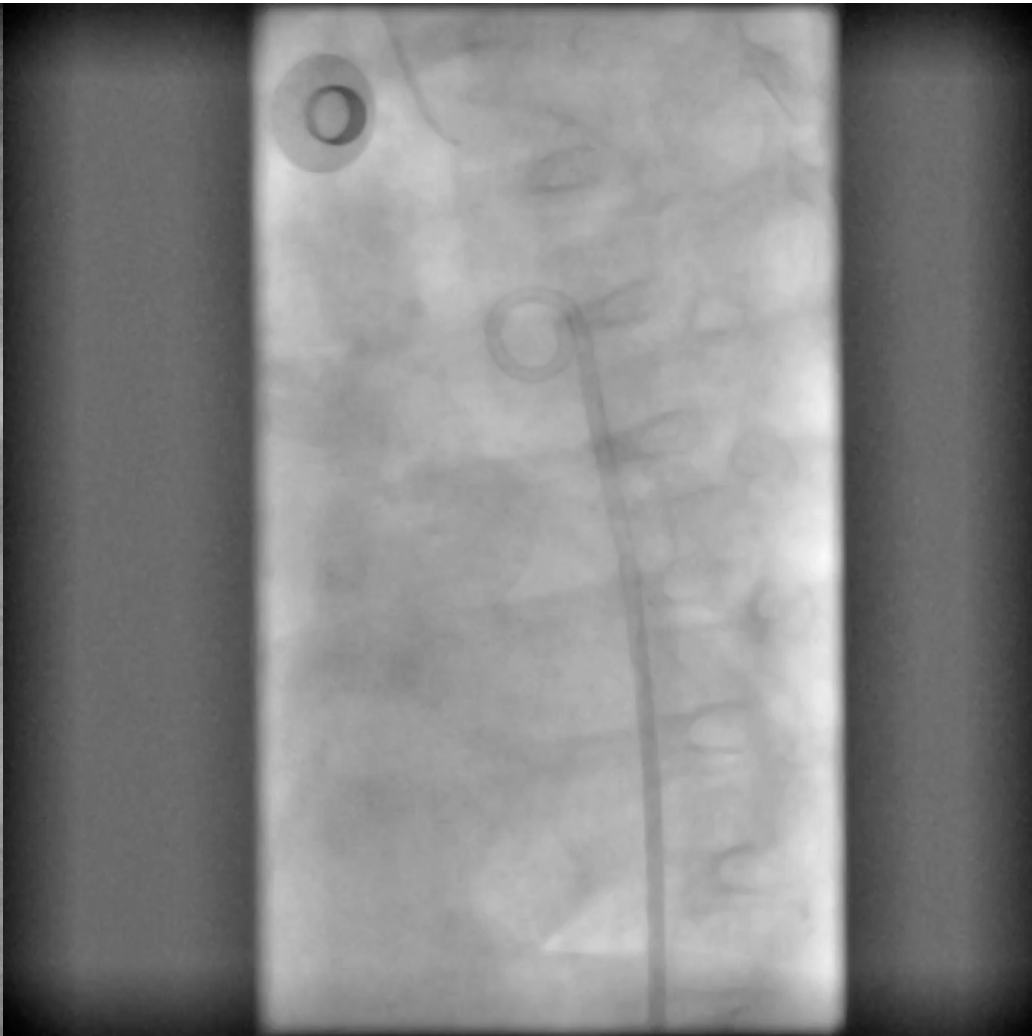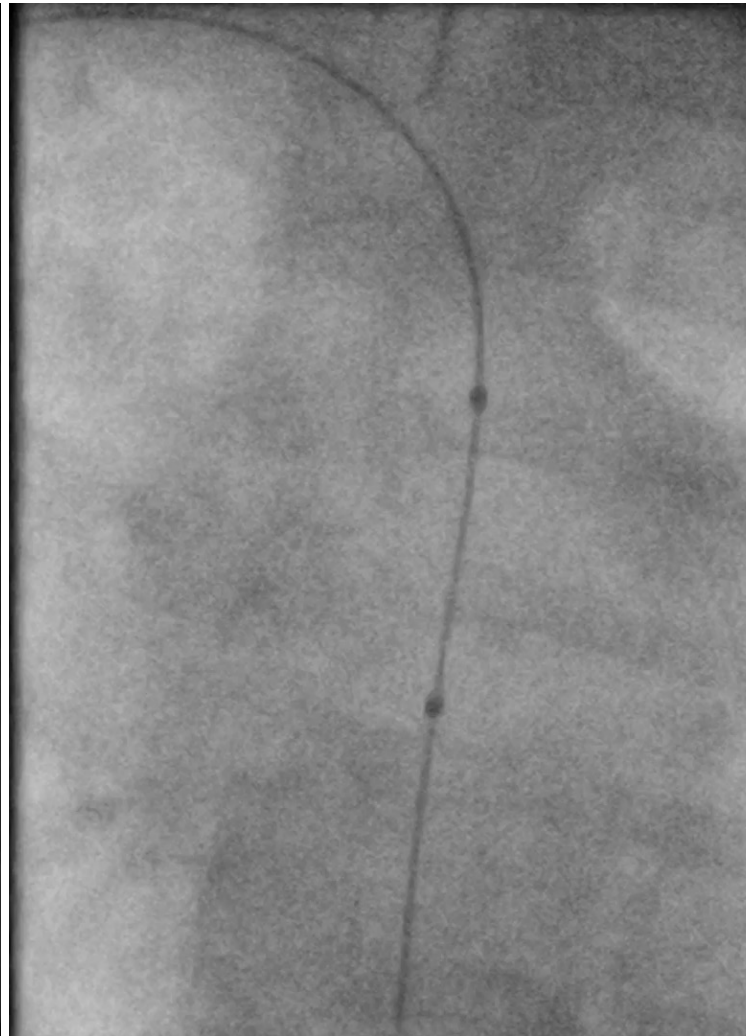
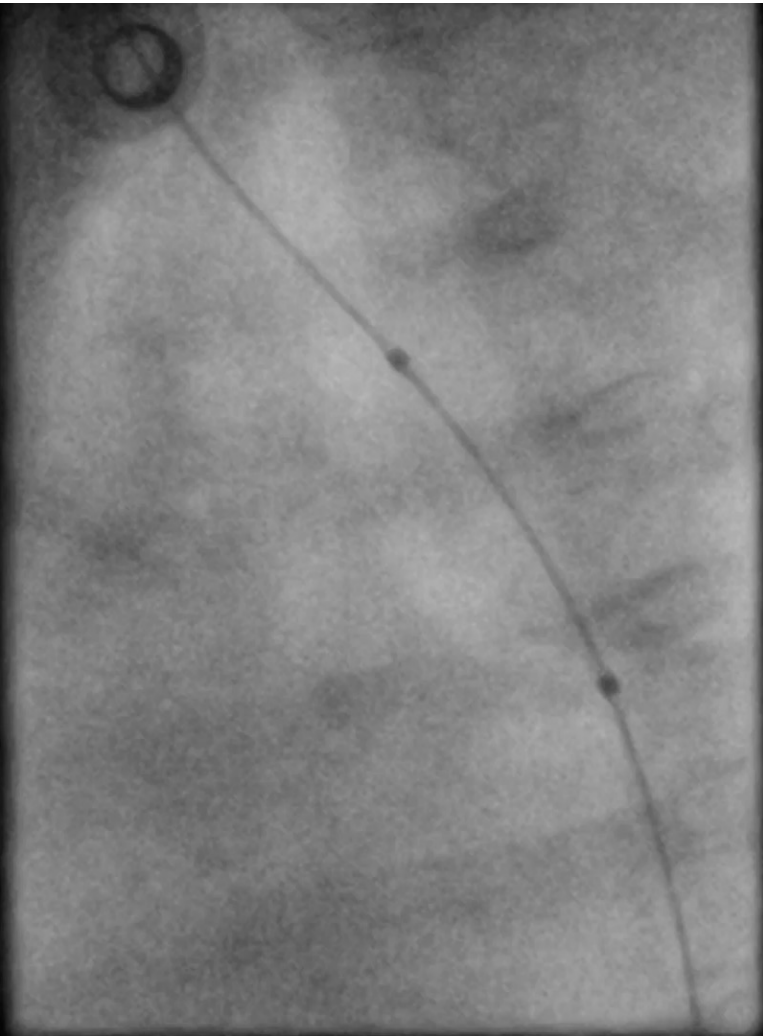Normaal



Afwijkend



Ballondilatatie Re - Coarctatie

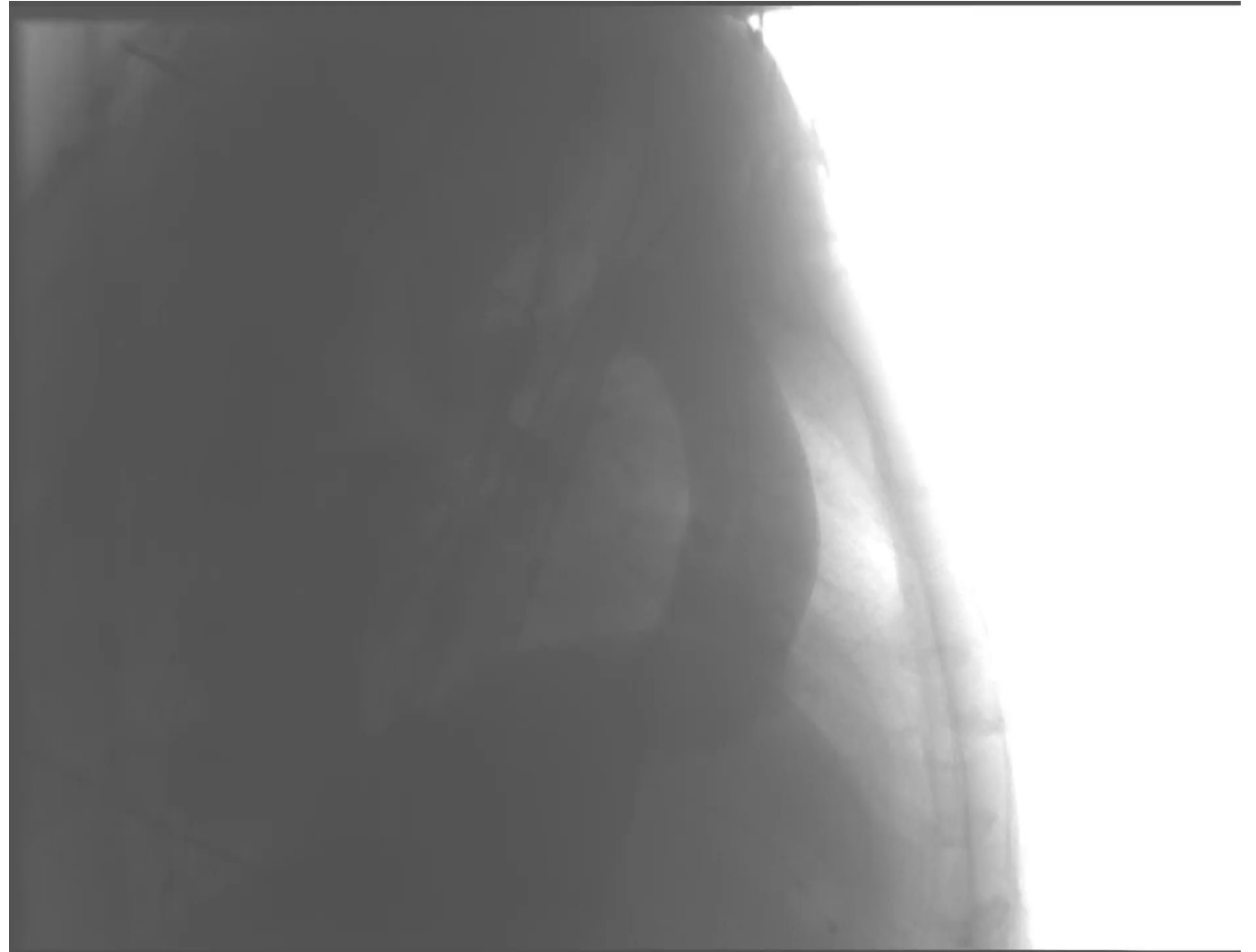
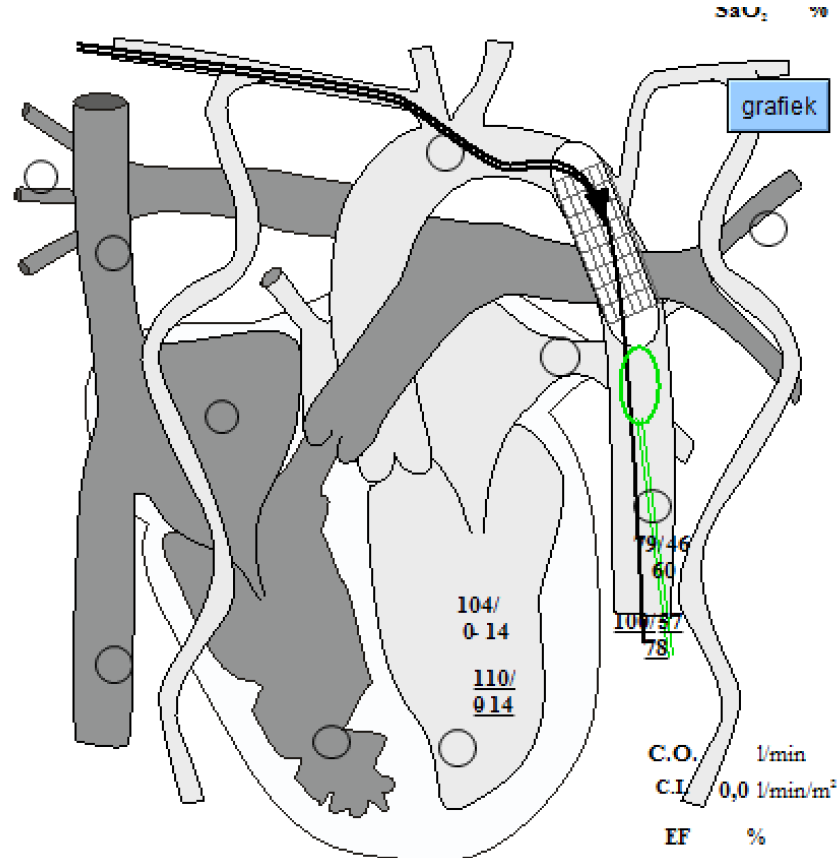


Voorbeeld catheterisatie als primaire behandeling

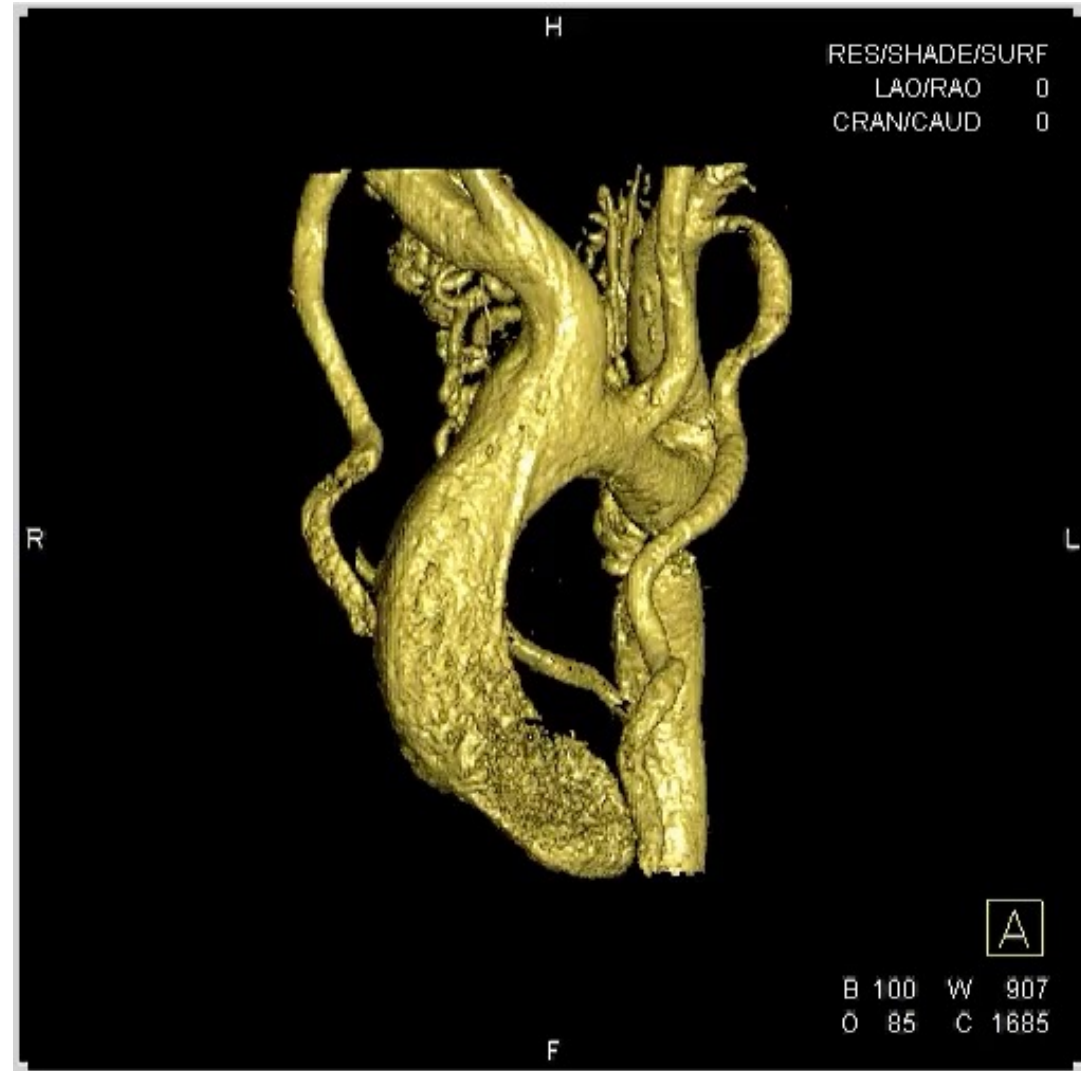
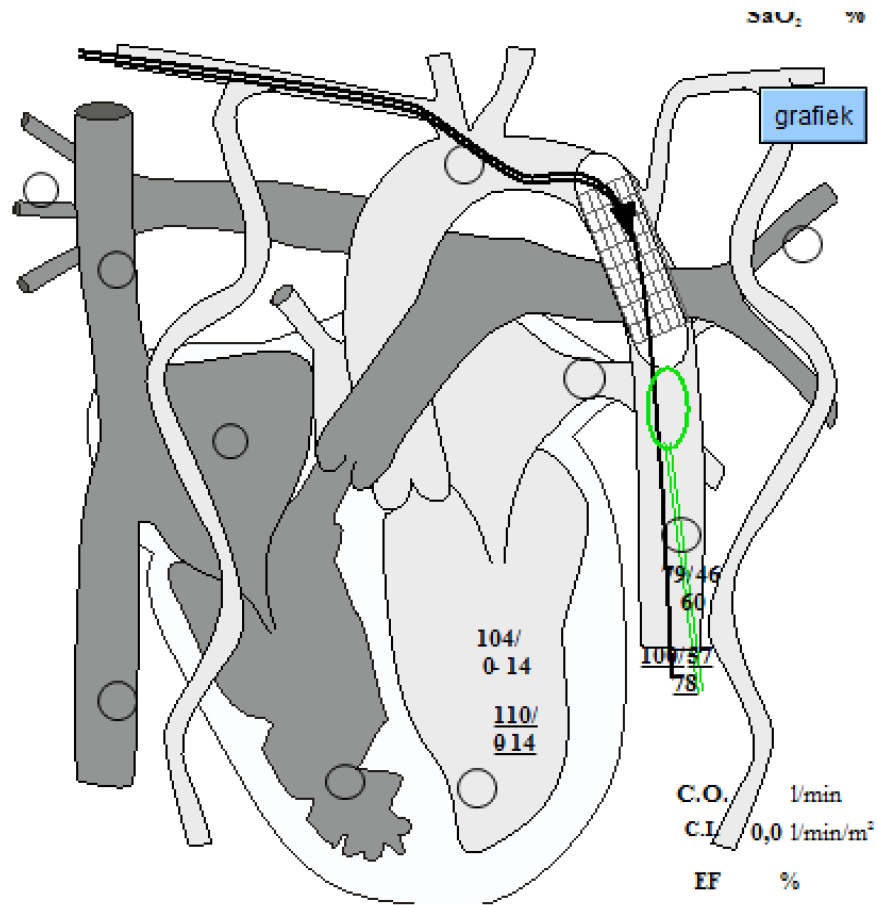
Bij ouder kind of volwassene

Indicatie: stent implantatie in natieve Coarctatie

Man 46 jaar
Hypertensie
Multi medicatie




Indicatie: stent implantatie in natieve Coarctatie

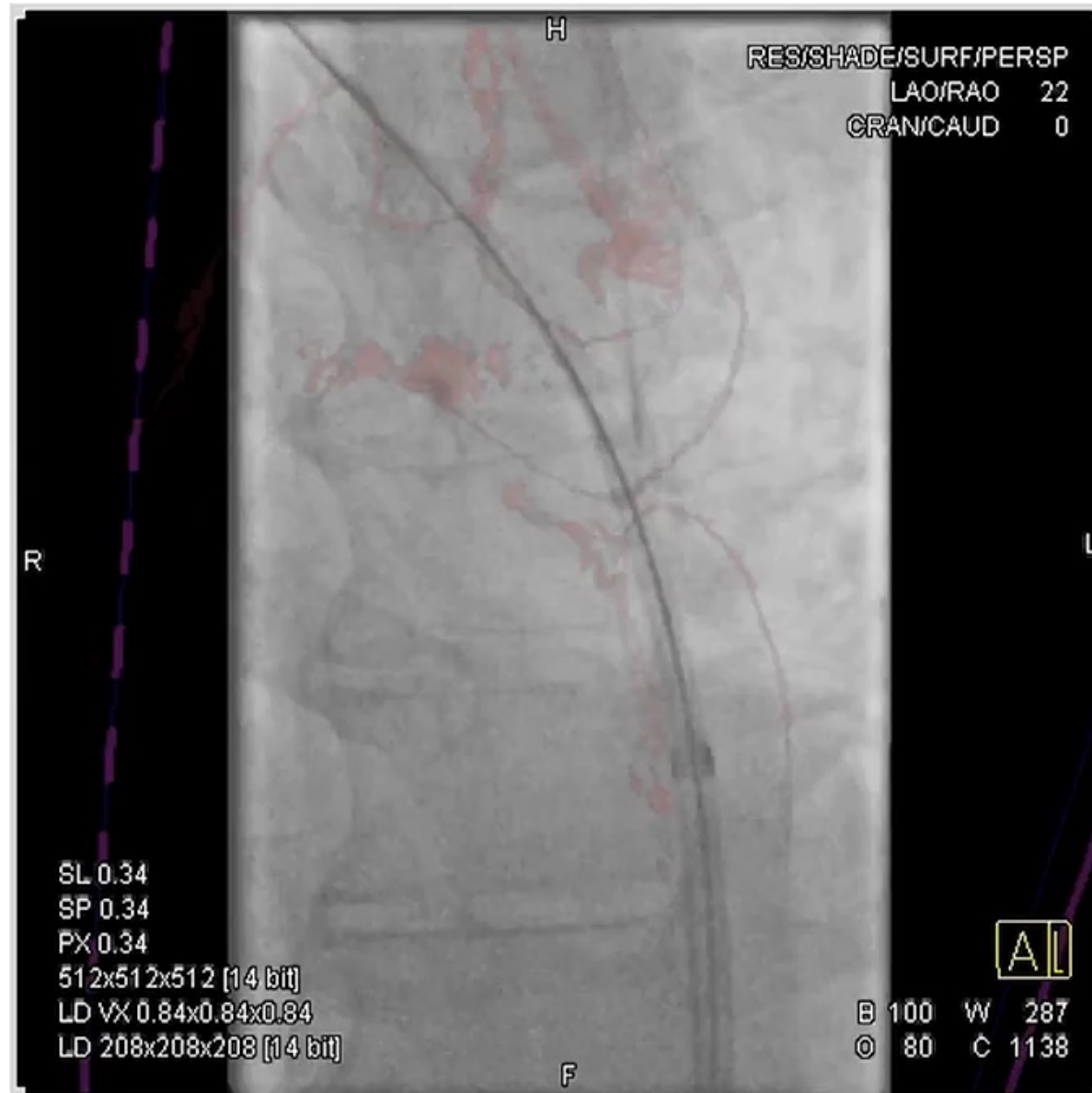

Indicatie: stent implantatie in natieve Coarctatie

Mini doorgang of niks ?



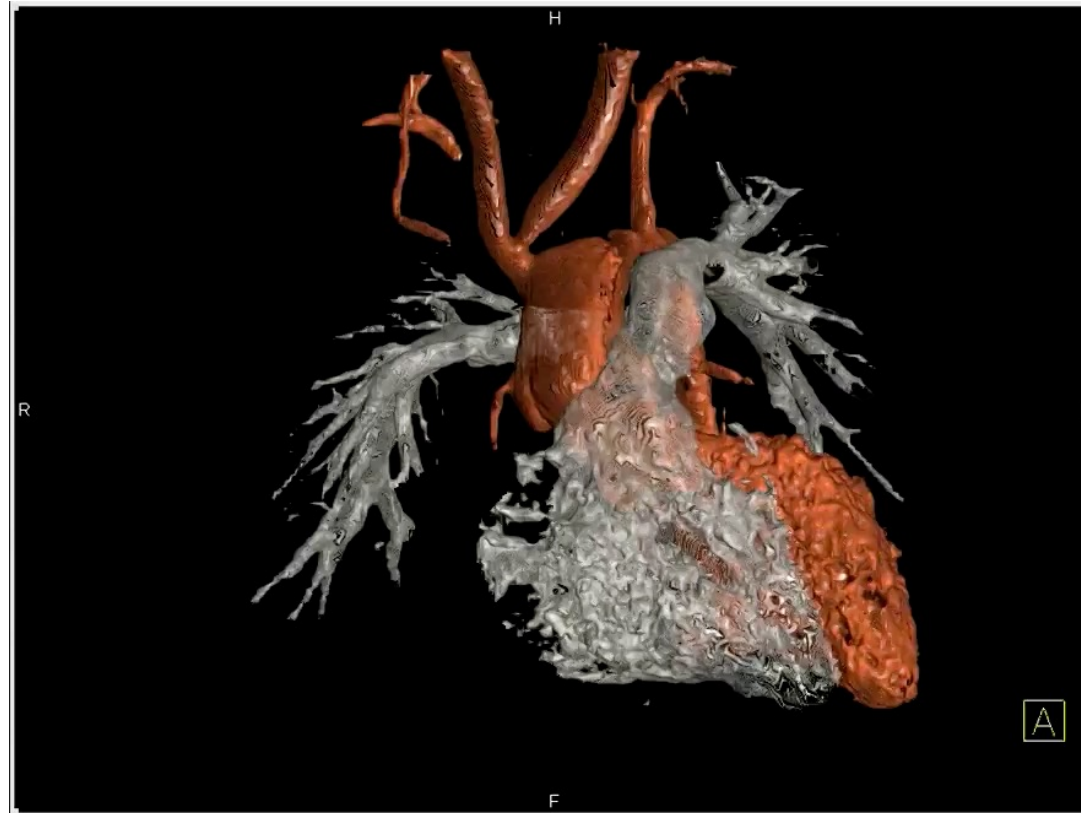
Indicatie: stent implantatie in native Coarctatie



Voorbeeld catheterisatie na eerdere hartoperatie

3D beeldvorming bij complexe anatomie

3D beeldvorming bij complexe anatomie



3D beeldvorming

Voor behandelaars




Voor patiënt en ouders

Grenzen verleggen

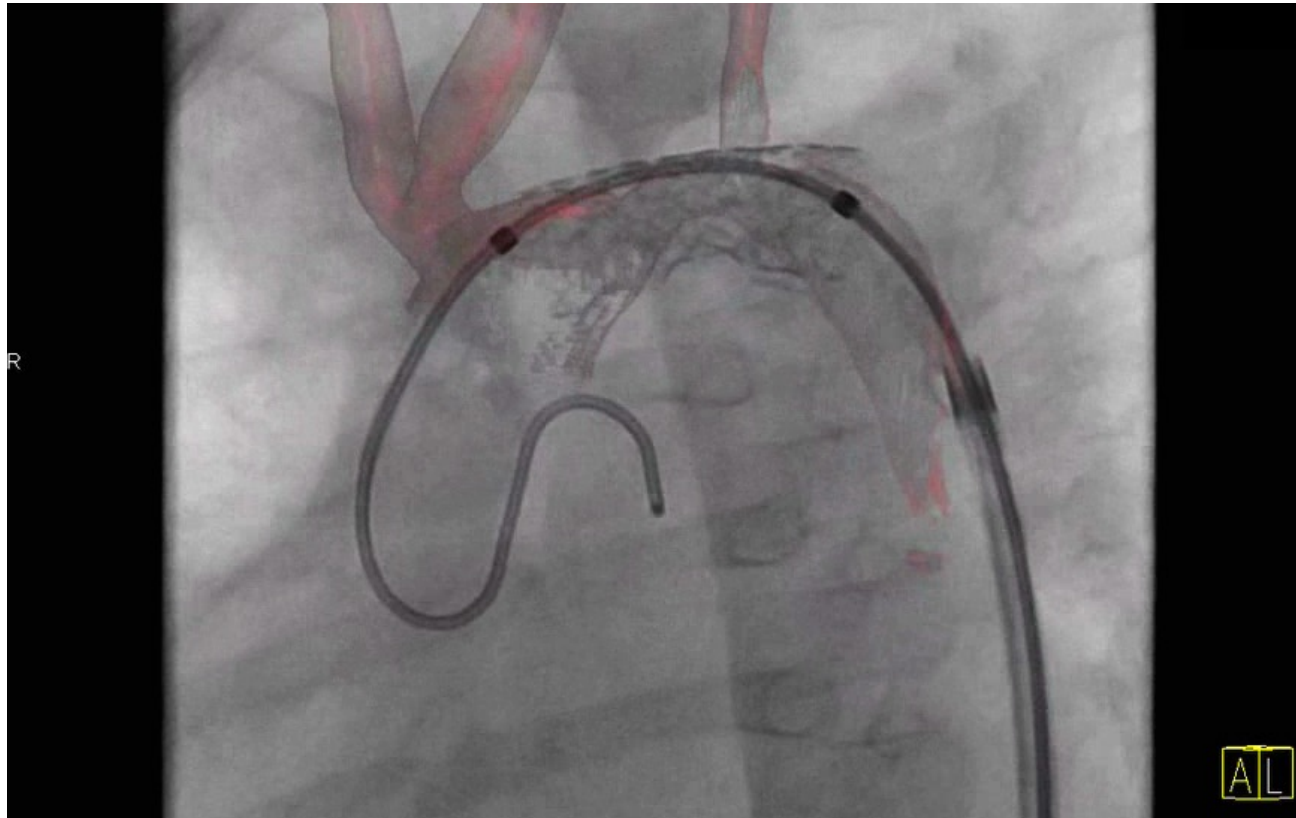
Uitbreiding arsenaal

Uitbreiding indicaties

Grenzen verleggen



3D beeldvorming bij complexe anatomie & Grenzen verleggen

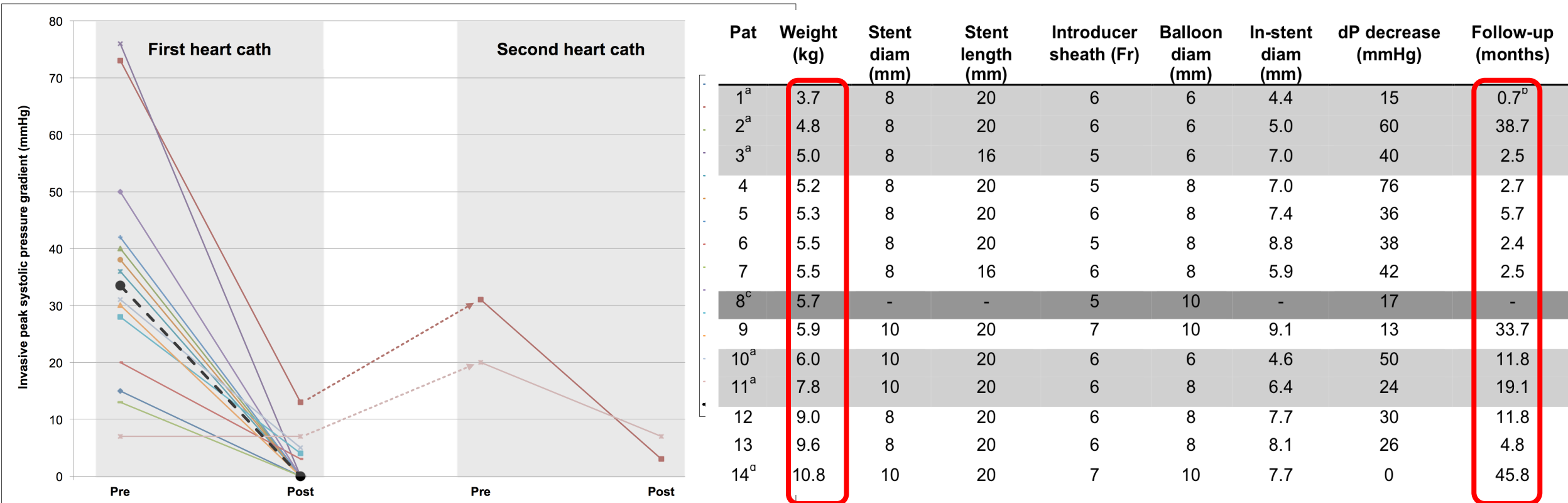


Grenzen verleggen

EuroIntervention. 2019 Oct 1. pii: EIJ-D-19-00157. doi: 10.4244/EIJ-D-19-00157. [Epub ahead of print]

Bare-metal stenting in (recurrent) coarctation of the aorta in children below 12 kg: initial results and mid-term follow-up.

van Kalsbeek RJ¹, Krings GJ, Molenschot MMC, Breur JMPJ.

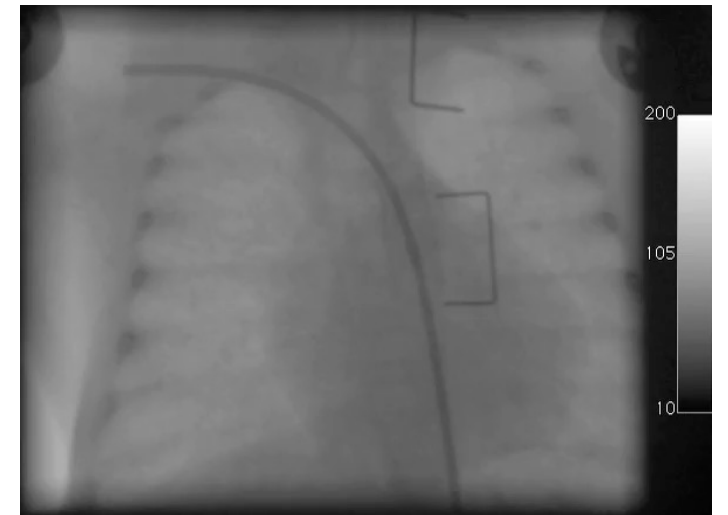
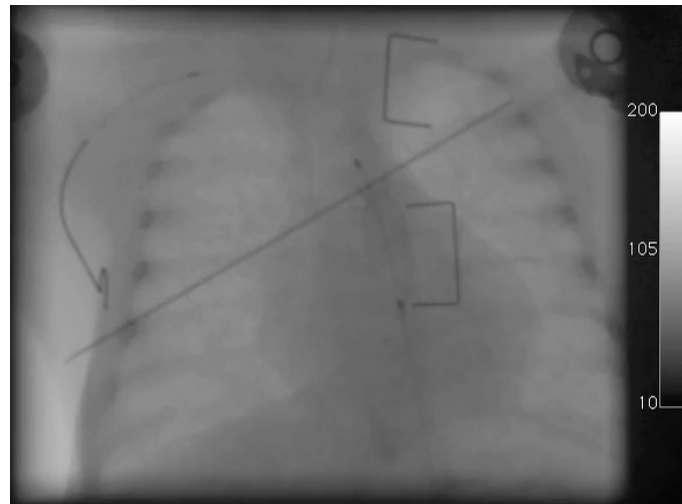
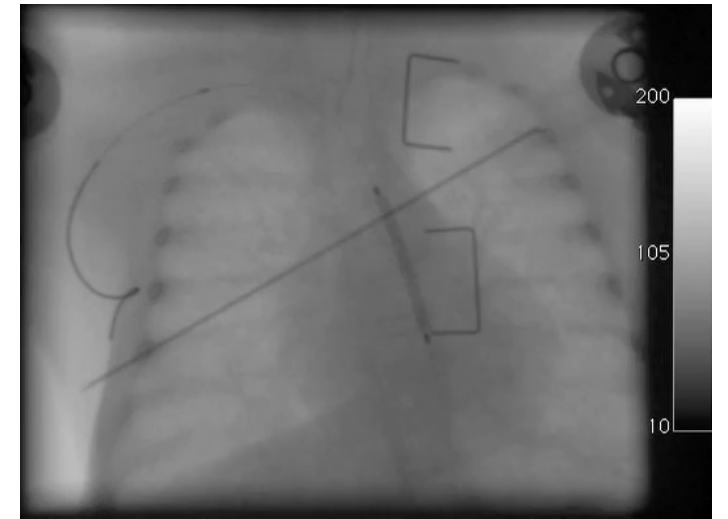
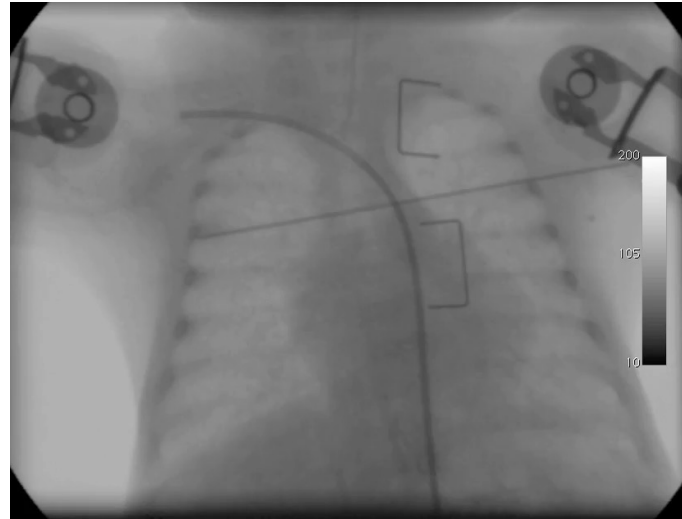
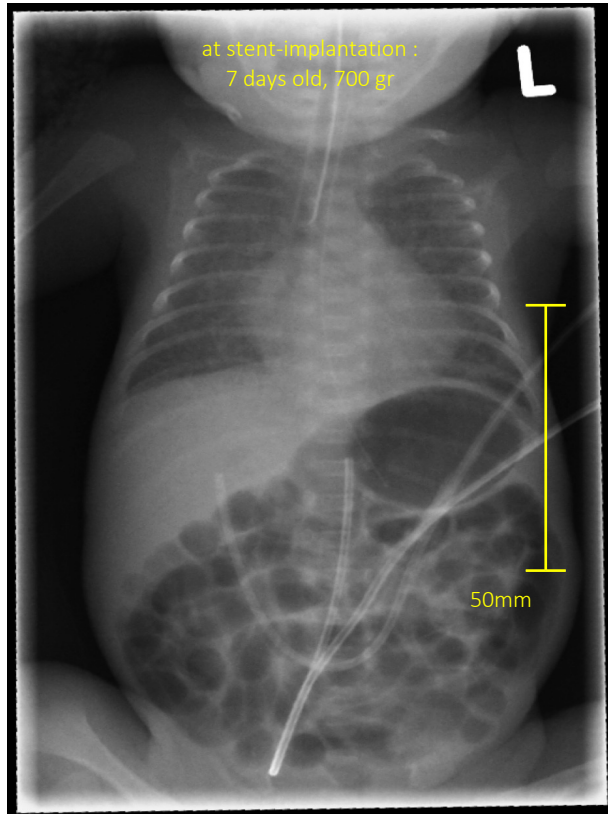


Grenzen verleggen

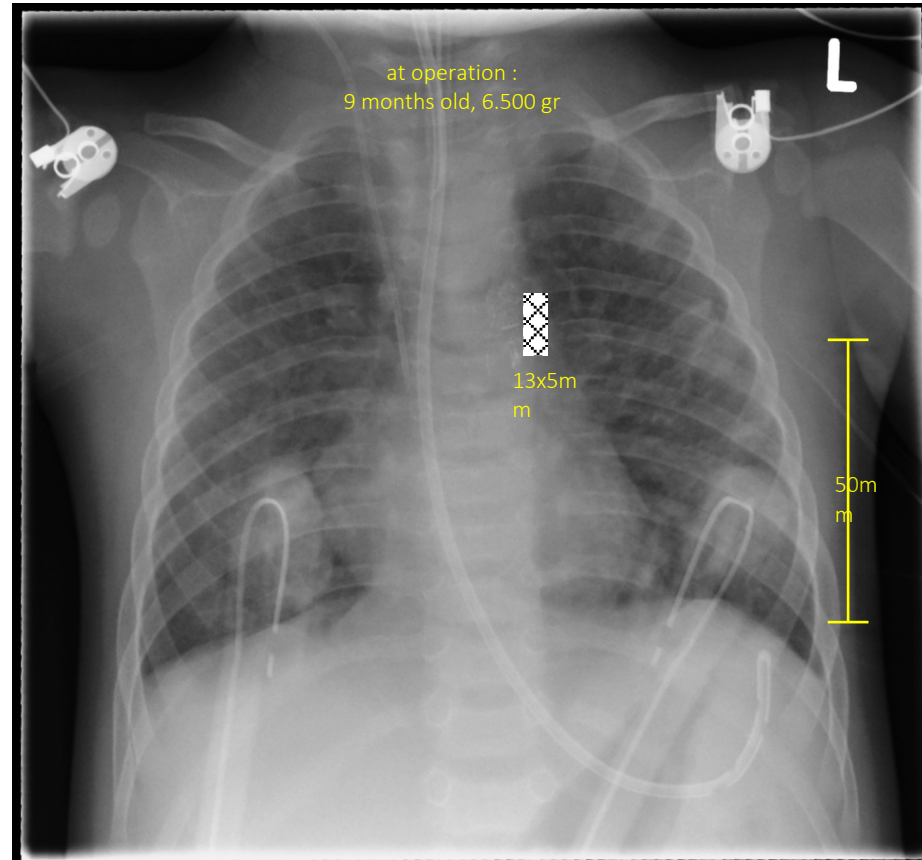
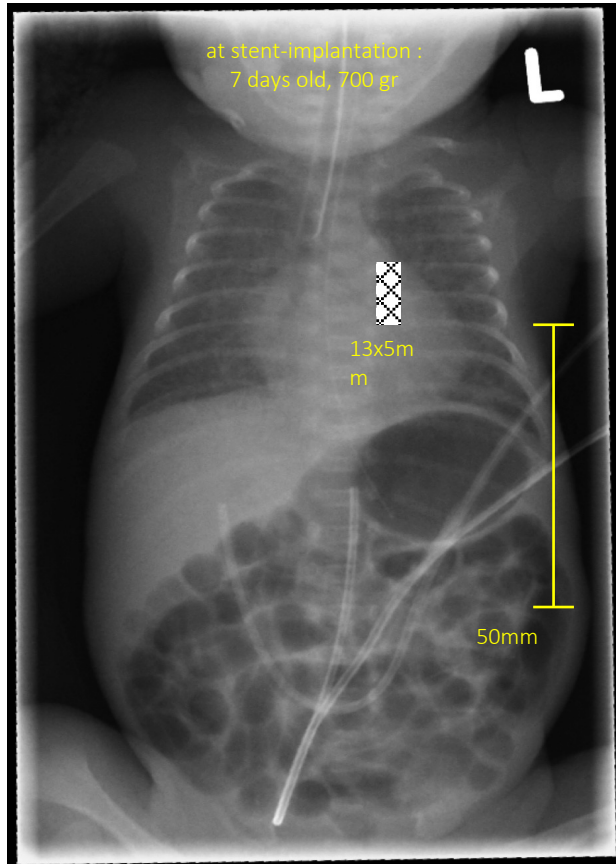
Gewicht...

.....How low can we go ?

Grenzen verleggen : 700 gram



Grenzen verleggen : 700 gram => 6,5 kg



Grenzen verleggen



Contents lists available at ScienceDirect

International Journal of Cardiology

journal homepage: www.elsevier.com/locate/ijcard



Short communication

Primary coronary stent implantation is a feasible bridging therapy to surgery in very low birth weight infants with critical aortic coarctation



Raymond Stegeman^{a,b,c,*,1,2}, Johannes M.P.J. Breur^{a,1}, Jörg Heuser^{e,1}, Nicolaas J.G. Jansen^{b,1}, Willem B. de Vries^{c,1}, Daniel C. Vijlbrief^{c,1}, Mirella M.C. Molenschot^{a,1}, Felix Haas^{d,1}, Gregor J. Krings^{a,1}

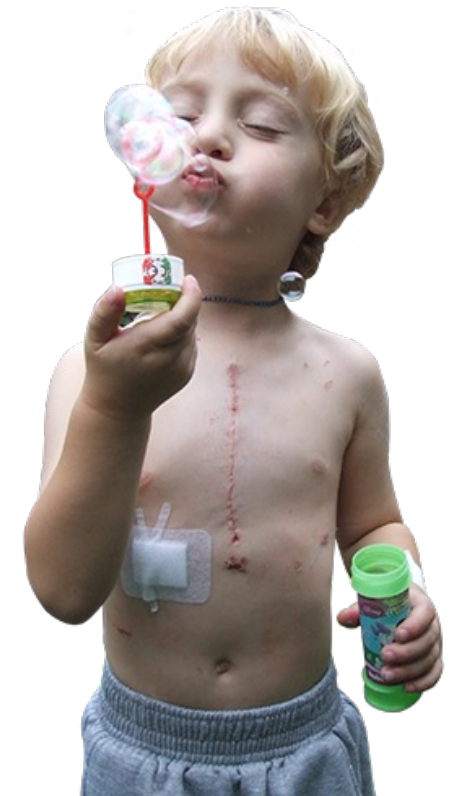Patient	Gestational Age (weeks)	Birth Weight (gram)	Gender	Age at diagnosis (days)	Indication
1	28	720	Female	0	Cardiac failure
2	27	765	Male	2	Cardiac failure
3	29	1000	Male	15	Cardiac failure
4	32	1220	Female	0	Severe hypertension
5	31	1380	Male	12	Cardiac failure
Median	29	1000	.	2	.

Grenzen verleggen : niet alleen de techniek telt

Griffiths Mental Developmental Scales

6/7 patienten: 2-ling

	Patients	Siblings
Age (months)	18 (range 6-38)	17 (range 6-38)
Developmental Quotient (normal value 100)	105 (range 96-113)	111 (range 96-115)



Kortom

Kinderhartcentrum Utrecht

.... Kwaliteit

- technisch
- vernieuwing
- van leven

.... Teamwork

- technisch
- voor kwaliteit van leven
- levensloopzorg





Dank voor uw aandacht